



Comparison between three decellularization protocol whit SDS in swine esophagus: a future option in veterinary medicine

Anna J.A. Santos¹; Ana LÍdia J. Delgado²; Karoline M. Souza³; Maria A. Miglino²

*Corresponding author: E-mail address: annajualvesdossantos@gmail.com

Abstract: Disease such as megaesophagus and esophagitis does not have a cure in animals. Esophagitis has treatments depending on it's degree, while me-gaesophagus has a palliative treatment, which can be recommended euthanasia in cases of a poor prognosis, cases that the esophagus transplant could be at use, although it is not described in literature. In this perspective, tissue bioengineering has techniques to create a minor immune response in transplants, as it removes the organ's genetic material, preserving the extra cellular matrix (ECM). Different protocols have been evaluated for swine esophagus decellularization, using sodium dodecyl sulphate (SDS) in concentrations 0,5%, 1,0% and 1,5% for seven days, analysing the remaining EMC integrity. It has been concluded that the material in 0,5% of SDS showed more integrity of the remaining EMC compared to the other concentrations, demonstrating that it is the best biological scaffold for future medical applications

Keywords: Decellularization. Tissues Bioengineering. Megaesophagus. Regenerative Medicine.

Introduction

According to König¹⁶ (2016), the esophageal structure contains four layers: adventitia, muscular, submucosa and mucosa; Diseases like megaesophagus and esophagitis are the main diseases that affect animal esophagus. Esophagitis is more common in dogs than in cats¹, consisting in the damage to the esophagus mucosa, in some cases affecting all the way to the submucosa and the muscular layer, depending on the severity and the agent that caused it². Megaesophagus consists of dilation and esophageal hypomotility, which can be idiopathic, congenital or secondary to other disease³.

Megaesophagus's etiologies are diverse, being congenital idiopathic, acquired idiopathic or secondary to other diseases. The main symptom is regurgitation, that can occur minutes or hours after the ingestion of food, its frequency varies, occurring weekly or daily³. Complications of the megaesophagus are inhalation pneumonia, and may lead to cough, fever, weight loss or even death⁴. The treatment is palliative, aiming for a greater absorption of nutrients in the gastrointestinal tract and a better quality of life. In general, it consists of a specific diet for each patient, with medication for the primary disease when necessary³. These dogs' feeding is made in a 45° angle or greater if possible, counting with gravity's support for the food to pass through the esophagus to the stomach⁴.

Esophagitis main prompter is gastric reflux during

procedures with anesthesia. Chronic emesis can cause the disease in case of a high intensity and frequency². The treatment in medium cases consists of nutritional management and light antacids. In more advanced cases, the treatment counts with nutritional management, more powerful antacids, or even the removal of the ill fragment through a partial esophagectomy⁵. These procedures can occur only in small portions of the organ, being indicated that the surgical removal be in the gap of 3 and 5 cm, resulting in surgical dehiscence in major portions⁶.

Since a complete esophagectomy is not viable nowadays, techniques for situations of a major affected portion of the organ were created. Examples are the use of small intestine's submucosa for repairing lessons of the cervical esophagus⁷, and the substitutions of the esophagus for a gastrotube using gastroplasty⁸. Although the techniques are effective, they can not completely replace esophagus function, which can lead to a bad nutrition after the operation and post-surgical complications⁹. Esophageal transplant could be an option in these cases, even though it is little described in literature in veterinary medicine.

As an option for transplants the regenerative medicine with advanced tissue engineering techniques. Tissue and organ decellularization techniques were and still are developing, aiming a minor immune response in procedures such as organs transplants. A tissue as a whole contains cells and extracellular matrix (ECM). The ECM has

¹ Universidade Anhembí Morumbi's Veterinary Medicine Student São Paulo (SP).

² Surgery Department: Domestic and Wild Animals Anatomy, Veterinary Medicine College and Universidade de São Paulo's Zootechnics, São Paulo (SP), Brazil.

³ Discent of the veterinary medicine course, University of Guarulhos, São Paulo (SP).

biomechanical properties, besides being responsible for cell survival. Decellularization is the removal of cells from a tissue or organ, resulting in the preserved ECM, which is named "biological scaffold". This process preserves the ultrastructure, biological activities and mechanical integrity from the tissue. The biological scaffold is very relevant for regenerative medicine, because it can be used in allogeneic transplants or even xenogeneic transplants, causing a minor immune response in the receptor¹⁰⁻¹¹.

Several decellularization protocols were already described, each one based on the type of tissues that compose the organ, amount of cells, density, lipidic content and other factors. Decellularization methods can be chemical, as an example detergents, biological, such as enzymes or physic, like temperature^{10,11}.

This study has the goal of suggesting and evaluating a swine esophagus decellularization protocol, aiming for its possible application in esophageal transplants surgeries in veterinary medicine.

Methodology

Ten (1 control and 9 samples for experimental design) swine esophagus fragments, of both sexes, weighing approximately 50g were obtained from the slaughterhouse in the city of São José do Rio Pardo-SP, in accordance with the Animal Experimentation Ethics Committee 1166080618. These Esophageal fragments were frozen at -80oC for at least 24 hours for storage and aid of cell lysis.

The organ was submerged in a phosphate buffered saline solution (PBS, 136,9 mM de NaCl, 26,8 mM de

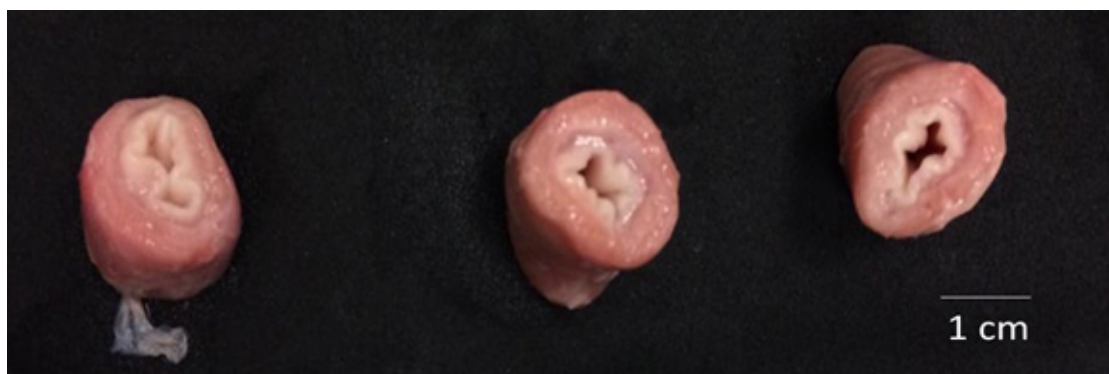
KCl, 14,7 mM de KH₂PO₄ e 8,1 mM de Na₂HPO₄.7H₂O, pH 7,2) followed by distilled water for cleaning it. Decellularization was made with sodium dodecyl sulphate (SDS), which is vastly used for this procedure¹⁰⁻¹⁴.

Three different protocols were established using the concentrations of 0,5%, 1% and 1,5% SDS, combining a physical method (agitation) and a chemical method (use of ionic detergent) with different concentrations. The decellularized oesophagus were washed before each protocol began with distilled water for 5 minutes. During the decellularization protocol, they were submerged in PBS 1x once a day for 5 minutes, for sinking in distilled water afterwards, returning then to SDS immersion in its concentrations in the shaker. All of them suffered through this process for seven days straight. At the end, the samples were fixed in 4% paraformaldehyde buffering during 48h, for microscopic analysis. Afterwards, they were dehydrated in ethanol, diaphanized in xylol and soaked in paraffin. Microsections of 5 μm were made using a microtome(# RM2265, Leica – Nussloch, GE) and transferred for glass blades. The blades were immersed in haematoxylin and eosin (HE) and Masson Trichome (TM) for the presence of nucleus and EMC collagen evaluation. Beside these analyses, the scanning electron microscopy technique was used⁵.

Results

The samples used in the decellularization protocol were previously photographed for analysing the macroscopic aspect, as it is shown in the figure 1.

Figure 1 – Samples before decellularization protocol.



Source: Own autorship, 2018.

The EMC varies in quantity and composition according to each tissue, being more present in tissues such as connective tissue, and minor amounts in epithelial, muscular and nervous. ECM represents the matter secreted by the resident cells, being responsible for the cells survival and may influence in their proliferation and differentiation. In a general form, ECM is composed of fibrous proteins, such as collagen and elastin. It is also composed of glycosaminoglycans, proteoglycans and glycoproteins^{10,18}.

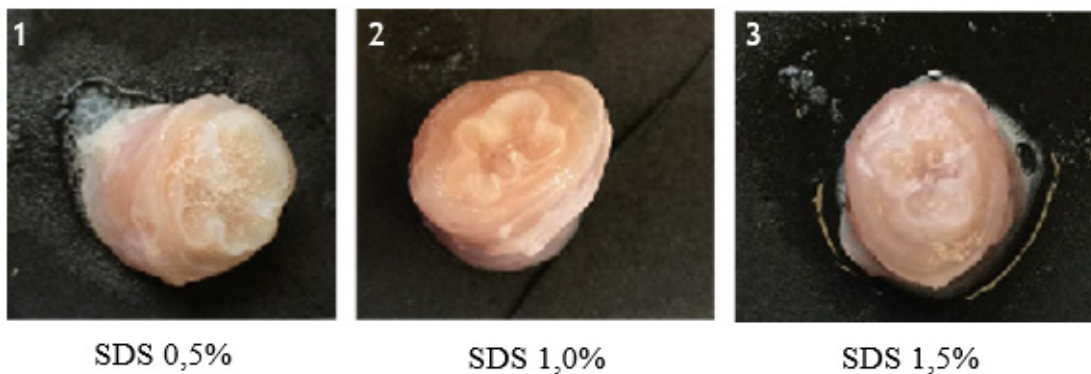
Subsequently to the decellularization protocol, the samples were photographed for efficiency evaluation. All the samples were “transparent”, which is a macroscopic indicative that the decellularization process occurred¹⁰. The translucent aspect is due to the removal of cells from the tissue, taking away the primary colour. The translucent aspect can be observed in Figure 2.

The macroscopic analysis was unclear, since all the

samples showed a preserved structure and a decellularized aspect. After noticing that, a light microscopy was made. In order to analyse the fragments searching for nucleus, the coloration Haematoxylin–Eosin (HE) and Masson Trichome (MT) for collagen presence methods were used.

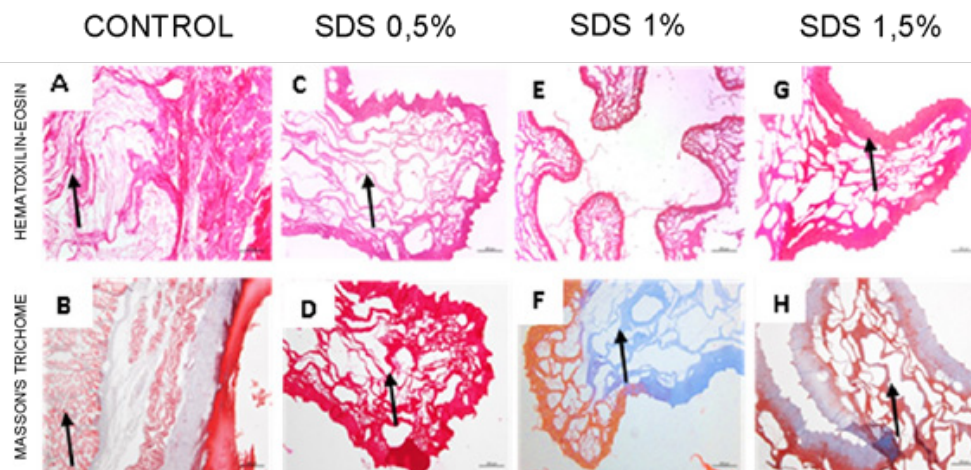
Haematoxylin is a dye in basic character, that paints acids structures in purple. The main example is the nucleus, containing DNA and RNA, both being acids. Eosin is an acid dye, painting basic structures in pink. It paints, among other things, EMC proteins¹⁸. TM is composed of haematoxylin, acid fuchsin, xylydine ponceau and green-blue, being used for giving colour to muscular tissue and collagen. The final results are: nucleus painted in brown; keratin, cytoplasm and muscular fibres in red; background as light green; collagen in blue or green¹⁹. The following image shows the light microscopies obtained from the control and the decellularized samples (Figure 3).

Figure 2 – Samples after decellularization protocol of 7 days. 1– Sample decellularized with SDS0,5%. 2– Sample decellularized with SDS 1%. 3– Samples decellularized with SDS 1,5%.



Source: Own authorship, 2018.

Figure 3 – **A**– Control coloration HE, whit mucosa intact (arrow). **B**– Control coloration MT, whit muscular layer (arrow). **C**– SDS 0,5% coloration HE, mucosa’s EMC is preserved. **D**– SDS 0,5% coloration MT, muscular EMC is preserved. **E**– SDS 1% coloration HE, does not show nucleus, but EMC is poorly preserved. **F**– SDS 1% coloration TM. **G**– SDS 1,5% coloration HE, does not show nucleus, but EMC is poorly preserved (arrow). **H**– SDS 1,5% coloration MT, mucosa and muscular poorly preserved.



Source: Own authorship, 2018.

All the samples were decellularized, not showing nucleus in any of them. As the ECM, evidenced by TM, there is a better preservation in the SDS 0,5% sample compared to the others, showing a better preservation of the ECM, painted in red. The samples decellularized using SDS 1,0% and 1,5% although presented no nucleus presence, showed a poor ECM preservation.

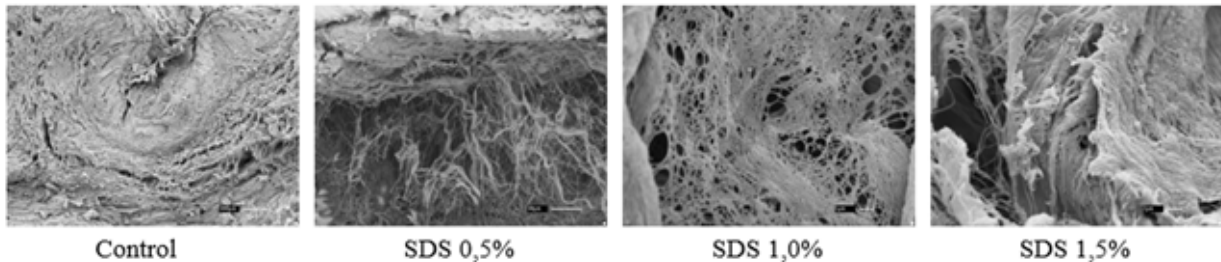
The SDS 0,5% sample has presented a better ECM preservation, demonstrated in pink in HE colouring and red in TM. The preservation of this sample was considerable in the mucosa and muscular regions when compared to others. Neither HE nor TM presented nucleus in the samples, which is a visual indicative of the decellularization process. Added to the macroscopic analysis, where the samples presented a transparent aspect, it has been concluded that the sample subjected

to the protocol of ionic detergent SDS 0,5% was the best between the samples evaluated.

It is important to understand the basic ECM constitution, which is a set of fibrous proteins, like collagen and elastin, and also extended glycoproteins, such as fibronectin and laminin, responsible for the adhesion cell-ECM²⁰. That information is important for qualifying the microscopic analysis. Since collagen is the most abundant protein and it has a structural function, its evaluation is very important for the decellularization process.

The microscopic analysis is a bidimensional model, it provides a poor representation of the ECM components organisation. Therefore, a scanning electron microscopy technique was required. This analysis provided the subsequential image.

Figure 4 – Scanning electron microscopy. Control – presents structural organisation of the esophageal tissue. SDS 0.5% shows the absence of cells with the best organised structure. 1% SDS shows a greater absence of cells and no structural organisation. 1.5% SDS also shows fewer cells and greater tissue disorganisation.



Source: Own authorship, 2018.

The control sample shows a preserved tissue, with cellular matter and a preserved ECM. Samples that were decellularized did not present cells, indicating that the decellularization process had succeeded. About the remaining ECM preservation, all of them had some level of degradation, being the 1,5% SDS sample the inferior preservation. Both 0,5% and 1,0% SDS samples obtained a satisfactory ECM ultrastructure preservation, although 0,5% SDS showed a better collagen fibres preservation.

Discussion

The decellularization protocol to be used depends on a lot of factors, such as quantity of cells in the tissue, density, lipidic content and thickness of the organ or tissue. The decellularization method can be physical, chemical or enzymatic^{10,11}.

Ackbar²¹ (2012) showed a decellularization protocol with SDS in sheep oesophagus, maintaining a good ECM preservation. Sitthisang²² (2021) had good results in the decellularization protocol of swine oesophagus, using SDS detergent and a perfusion technique. These studies had satisfactory results, but the focus was human medicine, unlike this study, that aims a veterinary application.

Regarding clinical applications of this protocol, it is a future option for clinical trials. Although organ transplants

are not much explored in veterinary medicine, it can be a valuable option for patients with poor prognostics, such as megaesophagus patients. In these cases, the treatment depends on the primary condition that is causing it, in most cases being idiopathic or neurological.

A 2020 study shows that in dogs, only 30,9% of the megaesophagus cases had a good outcome, while 19,8% had a persistence post treatment and 69,2% of the dogs died, either by secondary problems of the disease (49,9%) or euthanasia (20,2%). This, along with other results in literature, shows the demand for a more efficient treatment for this disease.

Conclusion

Organs transplantation may be an option for future use, considering its advanced tissue engineering techniques as a resource for a minimum immune response in transplantations. For future use in veterinary medicine, the decellularization protocol using SDS 0,5% explained in this study is an option, although research are needed, such as the recellularization protocol, immune responses in vitro and in vivo tests, having swine esophagus as a proof of concept for the future use of canine esophagus decellularization in veterinary medicine for clinical use in cases of comprehensive esophagitis or megaesophagus,

the decellularization protocol using 0.5% SDS is a good option, although more studies are needed for future application.

References

- [1] Little, Susan. *The cat: Internal Medicine*. [S.L.]: ABDR, 2012.
- [2] Sellon, R. K., Willard, M. D. (2003). Esophagitis and esophageal strictures. *Veterinary Clinics: Small Animal Practice*, 2003. **33**(5), 945–967.
- [3] Tams, T. R. Esophageal diseases. *TAMS, TR Small Animal Gastroenterology*. 2005, **2**:115–153.
- [4] Nelson, Richard, Couto, C. Guillermo. *Internal medicine of small animals*. Elsevier Brazil. 2015.
- [5] Fossum, T. H. et al. Digestive system surgery. *Small animal surgery*. 2002, 222–405.
- [6] Slatter, Douglas H. (Ed.). *Textbook of small animal surgery*. Elsevier Health Sciences, 2003.
- [7] DE SOUZA FILHO, Zacarias Alves et al. Use of porcine small intestine submucosa in the repair of cervical esophageal lesions. *Experimental study in dogs*. *Brazilian Surgical Act*. 2003, **18**(3).
- [8] Santos, Carlos Eduardo Meirelles of the. Analysis of thoracic esophageal removal and replacement: experimental study in dogs. 2008.
- [9] Ozeki, Masayasu et al. Evaluation of decellularized esophagus as a scaffold for cultured esophageal epithelial cells. *Journal of Biomedical Materials Research*. 2006, **79**(4), 771–778.
- [10] Crapo, Peter M.; Gilbert, Thomas W., Badylak, Stephen F. An overview of tissue and whole organ decellularization processes. *Biomaterials*. 2011, **32**(12), 3233–3243.
- [11] Gilbert, Thomas W., Sellaro, Tiffany I., Badylak, Stephen F. Decellularization of tissues and organs. *Biomaterials*, 2006, **27**(19), 3675–3683.
- [12] Badylak, Stephen F., Taylor, Doris, Uygun, Korkut. Whole-organ tissue engineering: decellularization and recellularization of three-dimensional matrix scaffolds. *Annual review of biomedical engineering*. 2011, **13**:27–53.
- [13] WALLIS, John M. et al. Comparative assessment of detergent-based protocols for mouse lung decellularization and recellularization. *Tissue Engineering Part C: Methods*. 2012, **18**(6), 420–432.
- [14] Keane, T.J., Badylak, S.F. The host response to allogeneic and xenogeneic biological scaffolding materials. *J Tissue Eng Regen Med*, 2015, **9**:504–511. doi: 10.1002/term.1874.
- [15] Bancroft, John., Gamble, Marilyn (Ed.). *Theory and practice of histological techniques*. Elsevier Health Sciences, 2008.
- [16] König, Horst Erich; Liebich, Hans-Georg. *Anatomy of Domestic Animals: Text and Colorful Atlas*. Artmed Publisher, 2016.
- [17] Dyce, Keith M., Wensing, Cornelius Jg., Sack, Wolfgang O. *Veterinary Anatomy Treaty*. Elsevier Brazil, 2004.
- [18] Junqueira, Luiz C., Carneiro, José. *Basic Histology: Text / atlas*. 11th ed. Rio de Janeiro: Guanabara, 2012. **50**:316.
- [19] NETO, Abel Dorigan. (2012) *TECHNIQUE IN CYTOPATHOLOGY: Reference Book 3: Histopathology Techniques*. Reference Book 3, Brasília-DF, **1**(1),36. Available at: http://bvsms.saude.gov.br/bvs/publicacoes/tecnico_citopatologia_cader-no_referencia_3.pdf. Accessed on: Oct 25 2019.
- [20] Pereira, Antonio L.a., Veras, Simone S.I., Silveira, Éricka J.d., Saabra, Flávio R.g. The role of extracellular matrix proteins and metalloproteinases in head and neck carcinomas: a bibliographic update. *Brazilian Journal of Otorhinolaryngology*, **71**(1),81–86. <https://dx.doi.org/10.1590/S0034-72992005000100014>
- [21] ACKBAR, Richard et al. Decellularized ovine esophageal mucosa for esophageal tissue engineering. *Technology and Health Care*. 2012, **20**:3, 215–223.
- [22] SITTHISANG, Sonthikan; LEONG, Meng Fatt; CHIAN, Kerm Sin. Perfusion decellularization of porcine esophagus: Study of two processing factors affecting the folded mucosal structure of the esophageal scaffold. *Journal of Biomedical Materials Research Part A*. 2021, **5**:745–753.